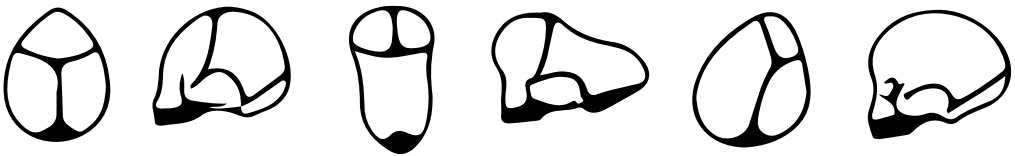


UNISUTURAL CRANIOSYNOSTOSIS

Simple or Complex?



Martijn J. Cornelissen